

# Screening Patients for Potentially Premalignant and Malignant Lesions: Performing a Head and Neck Examination

**Early detection of precancerous or cancerous lesions will help lower the burden of oral cancer diagnosed at an advanced stage.** A thorough examination of the soft tissues of the lips, oral cavity and oropharynx — particularly in patients with a positive history of tobacco and alcohol use — should be a routine part of a general medical exam. Once the healthcare provider is familiar with the anatomy of the oral cavity, screening for mucosal abnormalities should take less than 30 seconds.

Equipment and supplies for performing an oral examination include:

- An auroscope, small flashlight or headlamp, to provide adequate lighting
- A dental mirror or wooden tongue depressor, to retract the buccal mucosa and tongue
- Two 2x2-inch gauze squares
- Gloves
- Waterless antiseptic for hand washing (when soap and water are not available)

Seat the patient comfortably, either in a chair or on an examination table.

For consistency and accuracy, perform the oral examination in the same way and in the same order on every patient. Examine the extraoral area first, followed by the perioral and intraoral tissues.

- 1. Begin by evaluating the skin of the head, neck and face,** looking for asymmetry, crusts, fissuring and colour changes. Sun-damaged skin may cause actinic keratoses, a precursor to squamous cell carcinoma (see Figure A). Note any pigmented or suspicious lesions; if these lesions are present, the patient should be referred to a dermatologist.
- 2. Inspect lymph nodes** for enlargement, mobility and patient discomfort by bilaterally palpating regional lymph nodes, including pre-auricular and post-auricular nodes (Figure B), the parotid gland, anterior cervical and posterior cervical lymph nodes (Figure C), and submental nodes (Figure D) in the region of the submandibular gland. Lymph nodes should be freely movable. Painful nodes suggest an inflammatory process, whereas rock-hard, non-mobile lymph nodes are associated with malignancy. Lymph nodes that are larger than 2 cm and that persist for more than four weeks should be thoroughly evaluated by an otolaryngologist.
- 3. Inspect the lips,** paying close attention to their colour and texture. Note any surface changes, such as crusting, scaling or ulceration, that may suggest early cancer (see Figure A).

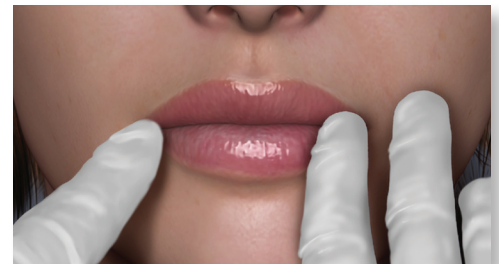

Figure A

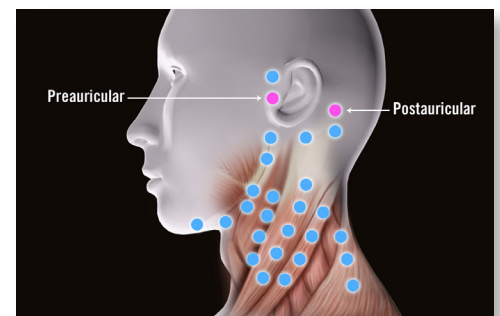


Figure B

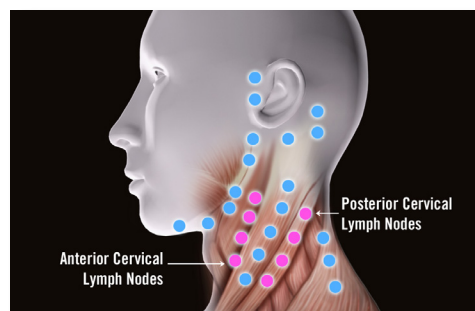


Figure C

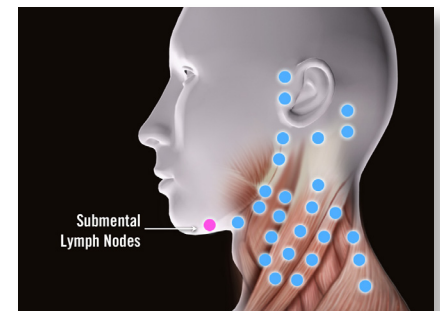


Figure D

**4. With the patient's mouth open, examine the mucosal side of the lips** and check for colour change, swelling or any other surface abnormalities. Bimanually palpate the upper and lower lips to screen for thickening or submucosal masses (see Figure E). Retract the buccal mucosa — first the right side, then the left.

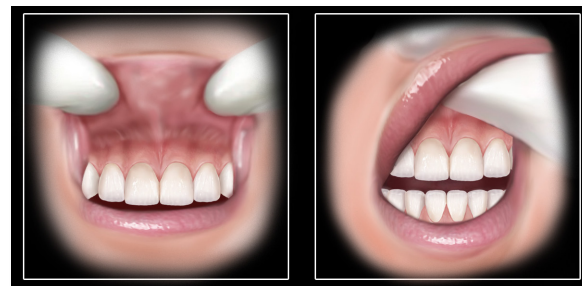

Figure E

**5. Examine the area extending from the angle of the lip commissure to the retromolar trigone area** (see Figure F). Note any changes in colour and texture, and inspect the area for any swelling.

**6. Examine the gingiva**, including both the labial and lingual aspects, and note any surface alterations, including colour and texture (see Figure G).

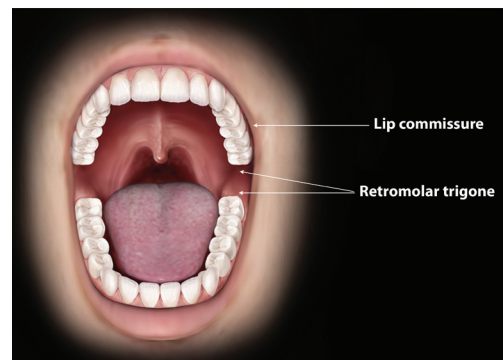


Figure F

**7. With the tongue at rest, inspect all surfaces** for swelling, ulceration, variation in colour or texture, or changes in the surface. Ask the patient to protrude his or her tongue, and move the tongue to evaluate mobility and symmetry. Grasp the tip of the tongue with a gauze square. Gently pull it to full protrusion and reflect to the left side, carefully inspecting the lateral and ventral surfaces for any surface abnormalities. Pay particular attention to the base of the tongue (see Figure H). With the other hand, palpate the tongue surface to screen for any areas of thickening or submucosal masses. Repeat this process on the other side.

**8. With the tongue elevated, examine the floor of the mouth.** Ask the patient to touch the roof of his or her mouth with the tip of the tongue, and inspect the anterior floor of the mouth for changes in colour or texture, or for other surface abnormalities. Bimanually palpate the right and left sides of the floor of the mouth to inspect the submandibular gland and associated lymph nodes, as well as any submucosal masses (see Figure H).

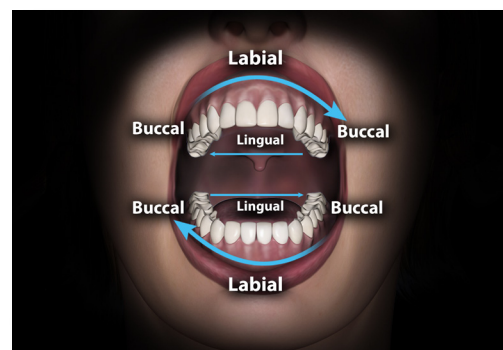


Figure G

**9. Ask the patient to tilt his or her head back gently**, so that you can examine the hard and soft palate for surface alterations or swellings. If necessary, depress the base of the tongue with the wooden tongue depressor to improve visualization when examining the soft palate and tonsil region (see Figure I). It is important to inspect the base of the tongue and tonsils to screen for asymmetry, as well as changes in surface colour or texture.

To view a video demonstration on how to perform a professional head and neck examination to screen patients for potentially premalignant and malignant lesions, go to [www.oralhealthed.com](http://www.oralhealthed.com).

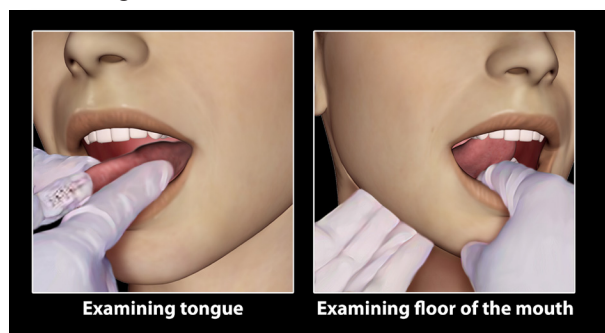


Figure H

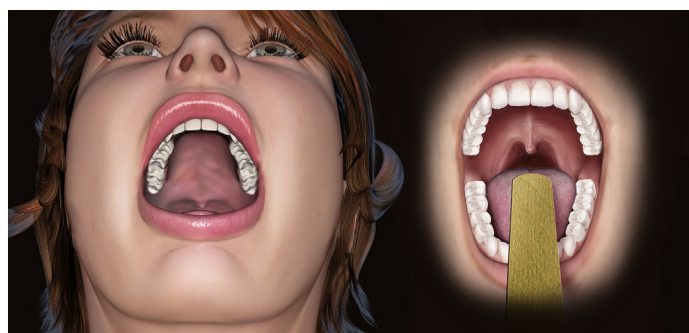

Figure I